

• Basic Research •

Early monitoring of radiotherapeutic effects of nasopharyngeal carcinoma xenografts in nude mice using ^{18}F -FDG PET-CT imaging

Jian-Wei Yuan¹, Yan-Lin Fen¹, Wei-Jun Xian¹, Xiao-Hong He¹, Bai-Hong Yuan¹, Qiu-Lian Ye²

¹ Department of Nuclear Medicine, Affiliated Foshan Hospital of Sun Yat-sen University, Foshan, Guangdong 528000, P. R. China; ² Department of Pediatrics, Affiliated Foshan Hospital of Sun Yat-sen University, Foshan, Guangdong, 528000, P.R. China

[Abstract] Background and Objective: Monitoring the therapeutic effects of radiotherapy for nasopharyngeal carcinoma (NPC) is critical to providing individualized treatment. This in-vivo study was initially designed to evaluate the therapeutic effect of radiotherapy using ^{18}F -fluorodeoxyglucose positron emission tomography with computed tomography (^{18}F -FDG PET-CT) imaging. **Methods:** ^{18}F -FDG PET-CT imaging was performed on all of the 10 nude mice bearing NPC xenografts before radiotherapy, and early-phase and delayed-phase PET-CT images were performed on 7 of the 10 mice. All mice were randomly divided into either a control group or a radiotherapy group. The 5 mice in the control group were immediately killed after the imaging and pathology were performed. After receiving radiotherapy of 12 Gy, 5 animals in the radiotherapy group were given ^{18}F -FDG PET-CT imaging on days 2, 4, and 6, and then were killed for pathologic evaluation. Regions of interest (ROI) technology was used to measure the tumor target/non-target (T/NT) ratio and the volume of the tumors. **Results:** The average T/NT ratios of early- and delayed-phase imaging were 1.806 ± 0.532 and 1.777 ± 0.597 , respectively, with no significance ($P > 0.05$). For the radiotherapy group, the average T/NT ratios for ^{18}F -FDG PET-CT before radiotherapy, and on days 2, 4, and 6 after radiotherapy, were 1.735 ± 0.466 , 1.818 ± 0.396 , 1.096 ± 0.101 , and 0.604 ± 0.108 , respectively. The tumor volumes were $(1.48 \pm 0.27) \text{ cm}^3$, $(1.57 \pm 0.31) \text{ cm}^3$, $(1.59 \pm 0.31) \text{ cm}^3$ and $(1.60 \pm 0.29) \text{ cm}^3$, respectively. The average T/NT ratios of day 6 after radiotherapy and the other time points were significant ($P < 0.05$). The average death ratio of the tumor cells was $(93.00 \pm 7.42)\%$ after 6 days of post-radiotherapy. **Conclusions:** ^{18}F -FDG PET-CT imaging can be used for the early assessment of radiotherapeutic effect of NPC in vivo. Day 6 after radiotherapy may be an appropriate time point for the imaging. However, the T/NT ratio measurement of delayed-phase imaging might make no sense for the diagnosis of NPC.

Key words: Nude mouse, nasopharyngeal carcinoma, xenograft tumor, tomography, emission-computed, radiotherapy

Early accurate assessment of the efficacy of radiotherapy for patients with nasopharyngeal carcinoma (NPC) is very important to improve survival rates, but also is a difficult problem for clinicians, because it is difficult to determine the abnormal mass, soft tissue swelling, and fibrosis or scar tissue on computed tomography (CT) after radiotherapy^[1]. ^{18}F -fluorodeoxyglucose positron emission tomography (^{18}F -FDG PET) uses positron radionuclide-labeled radiopharmaceuticals, detects the spatial

distribution, quantity, and change of labeled drugs and metabolites in vivo over time under physiologic conditions, and thus reflects the pathologic changes in vivo at the molecular level^[2]. It has been reported that FDG PET can effectively monitor the efficacies of radiotherapy and chemotherapy in patients with colon, lung, and head and neck cancers^[3-5]. In this study ^{18}F -FDG PET-CT imaging was applied on nude mice with NPC xenografts treated by radiotherapy to explore the value of ^{18}F -FDG PET-CT imaging in the early monitoring of the efficacy of radiotherapy for NPC and to provide a basis for clinical studies.

Materials and methods

Establishment of animal model

Experimental animals A total of 10 BALB/c strain male nude mice aged 4–6 weeks, with body weight between 16.3–19.8 g were provided by the Experimental Animal Center of Sun Yat-sen

Correspondence to: Jian-Wei Yuan; Tel: +86-757-83162208; Email: yjwei214@hotmail.com

This paper was translated from Chinese into English by CJC Medical Translation and edited by Hope J. Lafferty on 2010-02-11.

The Chinese version of this paper is available at <http://www.cjcsysu.cn/cn/article.asp?id=16585>.

Received: 2009-10-12; Accepted: 2010-01-04

Grant: Wu Jie-Ping Medical Foundation (No. 320.6750.06113); Guangdong Provincial Medical Technology Research Foundation (No. A2006657)

University [Animal qualified certificate: SCXK (Guangdong) 2008-0020]. They were raised in a specific pathogen-free (SPF) environment in laminar flow racks of the SPF animal room in the Experimental Animal Center of Sun Yat-sen University, with a constant temperature, no noise, air laminar flow filtration, and free sterile water and food.

Tumor cell line Poorly differentiated human NPC cell line CNE-2 was provided by the Experimental Animal Center of Sun Yat-sen University. Fetal calf serum was purchased from Hangzhou Sijiqing Biological Engineering Material Co., Ltd. RPMI-1640 culture medium and trypsin were purchased from Sigma-Aldrich in the United States.

Tumor injection CNE-2 cells were cultured with RPMI-1640 containing 100 u/mL penicillin and 100 u/mL streptomycin and 15% fetal calf serum in a 5% CO₂ incubator at 37°C for 1 week. When the cells grew into a full bottle, the digestive juice with a 1:1 mixture of 0.25% trypsin and 0.02% ethylenediamine tetraacetic acid (EDTA) was used to make a cell suspension of 1.0×10^6 /mL, and then 0.2 mL of the cell suspension was subcutaneously injected into the right axilla of the mice with 7-gauge needles. The animal experiments were conducted when the largest tumor diameter was more than or equal to 1.0 cm.

Experimental grouping and treatment

All 10 mice with the NPC xenograft received ¹⁸F-FDG PET-CT imaging before grouping. To observe the diagnostic value of the delayed imaging in NPC, 7 randomly selected mice received 1 h early and 3 h delayed PET-CT imaging, and the tumor target/non-target (T/NT) ratio was measured at the early and the delayed imaging. Then 10 mice with the established model of the NPC xenograft were randomly divided into a control group and a radiotherapy group, with 5 in each group. The 5 mice in the control group were killed immediately after PET-CT imaging before radiotherapy, tumor specimens were obtained and examined pathologically, and the tumor T/NT ratios were determined. The 5 mice in the radiotherapy group received repeated PET-CT imaging on day 2, day 4, and day 6 after radiotherapy, and were killed immediately after the PET-CT imaging on day 6. The tumor specimens were then obtained and examined pathologically and the tumor T/NT ratios at different times after radiotherapy were determined.

Radiotherapy

The F34-1 type deep X-ray therapy unit from Beijing Dongfanghong Medical Instrument Factory was used for radiotherapy. Exposure conditions included voltage at 120 kV, current at 12 mA, focal skin distance at 40 cm, filtration plate at 0.25 mmCu, and the amount of air was 600 cGy/fraction. When receiving radiotherapy, the mice were fixed in a specially designed plexiglass holder, one mouse each time, without anesthesia, with the tumor exposed and the non-irradiated sites shielded by lead.

Imaging method

Imaging devices and imaging agents A Philips GEMINI PET-CT imaging instrument with MX8000 2-slice spiral CT was used. The ¹⁸F-FDG was provided by the Guangzhou Isotope Center.

Imaging conditions and parameters All mice fasted overnight but were allowed to drink before imaging. After fixed by a custom device, the mice were injected with 7.4 MBq of ¹⁸F-FDG via the tail vein with a 4.5-gauge needle. After 1 h the mice were fixed in a custom plexiglass holder by a wide transparent tape, placed on the scanning bed, and then located in scanning field by laser positioning. CT scans were performed first with scan parameters including 120 kV, 160 mA, slice thickness of 5 mm, pitch at 1.0, and then the launch data were collected by three-dimensional acquisition with the routine 3 min per bed position. CT and PET data were transferred to the PET View workstation for PET image reconstruction and image fusion processing. CT data were used for nonuniform transmission attenuation correction of PET reconstruction, and RAMLA three-dimensional reconstruction was used to get transverse, coronal, and sagittal images. The acquisition time of 3-h delayed imaging was 5 min per bed position and the remaining conditions of acquisition and image processing technology were the same with 1-h early imaging. The same reconstruction parameters and semiquantitative measurement methods were used for all images.

Determination of T/NT ratios Based on the computer-generated PET-CT fusion images, regions of interest (ROI) techniques were used to determine tumor T/NT ratios and for quantitative analysis.

Measurement of tumor size On CT images the ROI technique was applied to measure the tumor volumes of the NPC xenografts in the 5 mice in the radiotherapy group before radiotherapy and on days 2, 4, and 6 after radiotherapy.

Pathologic and immunohistochemical examinations

The tumor specimens of the NPC xenografts in all 10 mice were fixed by 10% formalin, embedded in paraffin, and sliced, stained by hematoxylin and eosin, and observed under a 20x light microscope to examine the death cell proportion. The EnVision method was used for immunohistochemical Ki-67 staining of the slices. Mouse anti-human monoclonal antibody working fluid and Ki-67 test kits were purchased from Shanghai Gene Technology Co., Ltd. The nucleus stained yellow was counted as the standard for Ki-67 positive cell staining. Ten representative visual fields were selected under high-power microscope (×400) with 100?tumor cells counted in each field, and the percent of positive cells was calculated while stained positive cells less than 10% or no yellow staining was considered Ki-67 negative.

Statistical analysis

All data were shown as mean ± standard deviation. SPSS version 13.0 was used for statistical analysis. Paired *t* test was used for the comparison between the two groups, analysis of variance was used for the comparison among multiple groups, and the least significant difference (LSD) method was used for comparison within a group. *P* < 0.05 was considered statistically significant.

Results

The results of pathology and immunohistochemistry

Pathologic result showed that in the control group tumor

cells grew into nests with uniform nuclei, clear eosinophilic nucleoli, and occasional small areas of necrosis. In the radiotherapy group, tumor tissue had large areas of necrosis with some tumor cells surviving at the tumor edge. The expression rate of Ki-67 ranged from 58.5% to 82.6% and 2.0% to 5.8% for the control group and the radiotherapy group, respectively. The pathologic and immunohistochemical results of the control and radiotherapy groups are shown in Table 1.

Table 1 Pathology and immunohistochemical results in CNE-2 tumor xenografts of the radiotherapy group after 6 days as compared to the control group

Group	n	Ki-67 (%)	Necrosis (%)
Control group	5	67.3 ± 9.80	12.6 ± 11.8
Radiotherapy group	5	3.62 ± 1.43	93.0 ± 7.42

Ki-67, proliferation marker; necrosis (%), percent of necrosis

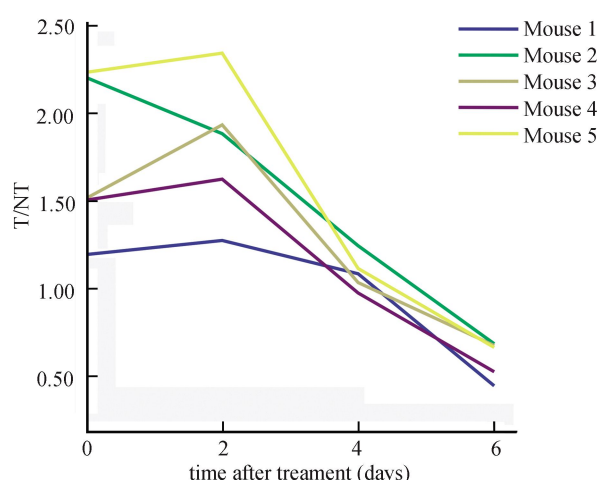


Figure 1 In the radiotherapy group, the tumor target/non-target (T/N) ratios at different times of pre- and post-radiotherapy with animal models of nasopharyngeal carcinoma (NPC) xenografts in nude mice

The results of PET-CT imaging

The T/N ratios of xenografts in the control group and the radiotherapy group before radiotherapy were 1.503 ± 0.614 and 1.735 ± 0.466 , respectively, without significant differences ($t = -0.595$, $P = 0.584$). In the radiotherapy group, the T/N ratios of xenografts before radiotherapy and on days 2, 4, and 6 after a continuous 2-day deep X-ray radiotherapy of 12 Gy were 1.735 ± 0.466 , 1.818 ± 0.396 , 1.096 ± 0.101 , and 0.604 ± 0.108 , respectively, as shown in Figures 1 and 2. The T/N ratio of xenografts on day 6 after radiotherapy had significant differences compared with those before radiotherapy and on days 2 and 4 after radiotherapy ($F = 5.954$, $P = 0.006$; $P < 0.001$, $P < 0.001$, and $P = 0.025$).

Tumor volumes were measured by the ROI technique on CT images, and the tumor volumes of the NPC xenografts before radiotherapy and on days 2, 4, and 6 after radiotherapy were $(1.48 \pm 0.27) \text{ cm}^3$, $(1.57 \pm 0.31) \text{ cm}^3$, $(1.59 \pm 0.31) \text{ cm}^3$ and

$(1.60 \pm 0.29) \text{ cm}^3$, respectively.

The results of early and delayed PET-CT imaging

After the injection of the radioactive agents, 1-h and 3-h delayed imaging were performed in 7 animals with NPC xenografts, and the T/N ratios in the early and delayed PET-CT images were 1.806 ± 0.532 and 1.777 ± 0.597 without statistical significance ($t = 0.280$, $P = 0.789$).

Discussion

For the oncologist, assessing early efficacy is crucial for reasonable individual treatment. At present, the efficacy assessments in patients with malignant tumors are mainly based on tumor size after treatment. However, the morphologic changes of tumors after treatment lags behind the death of tumor cells, and reduced tumor after treatment possibly still contains a number of tumor cells. So traditional imaging methods, such as CT and magnetic resonance imaging (MRI), have low sensitivity and specificity in early efficacy assessments^[6]. Through visual or quantitative analysis, ^{18}F -FDG PET-CT provides a reliable basis for early assessment of tumor metabolism and the determination of tumor residue at clinical or subclinical levels after treatment.

Radiotherapy can lead to early acute inflammatory responses resulting in high metabolism performance on ^{18}F -FDG PET, which may be confused with the high metabolism of the tumor, so there is no unified point of view about how long after radiotherapy is suitable for ^{18}F -FDG PET-CT imaging, and it is quite different among scholars. Mitsuhashi *et al.*^[7] and Yen *et al.*^[8] showed that FDG PET examination at 3–4 months after radiotherapy could better assess the treatment effect and at the same time PET-CT showed the morphologic and metabolism changes of the tumor with mutual complementary information. Peng *et al.*^[9] thought that the best time to assess whether there was residue or recurrence of NPC should be 6 months after radiotherapy. A study of ^{18}F -FDG PET imaging in nude mice with squamous cell carcinoma xenografts conducted by Molthoff *et al.*^[10] showed that the tumor T/N ratio demonstrated a significant downward trend at the 4th day after radiotherapy and the trend continued. However, for patients with NPC, monitoring and evaluating the efficacy of radiotherapy as soon as possible is particularly important for conducting reasonable individual therapy and extending survival times. The objective of this study in nude mice with NPC xenografts treated by radiotherapy was to explore the imaging time and feasibility of ^{18}F -FDG PET-CT imaging in monitoring the early efficacy of radiotherapy for NPC.

The NPC epithelial cell line CNE-2 used in this study has stable biologic characteristics and good radiosensitivity, grows fast and is suitable for the establishment of a nude mice model with NPC xenografts for radiotherapy, and is the appropriate material for experimental therapy of NPC in vitro. The imaging results showed that all xenografts in this study had good imaging with nice contrast before radiotherapy. Before radiotherapy, the T/N ratios in the control and radiotherapy groups had no significant differences ($t = -0.595$, $P = 0.584$). In this study, the 5 mice in the radiotherapy group received 12 Gy of radiotherapy (6

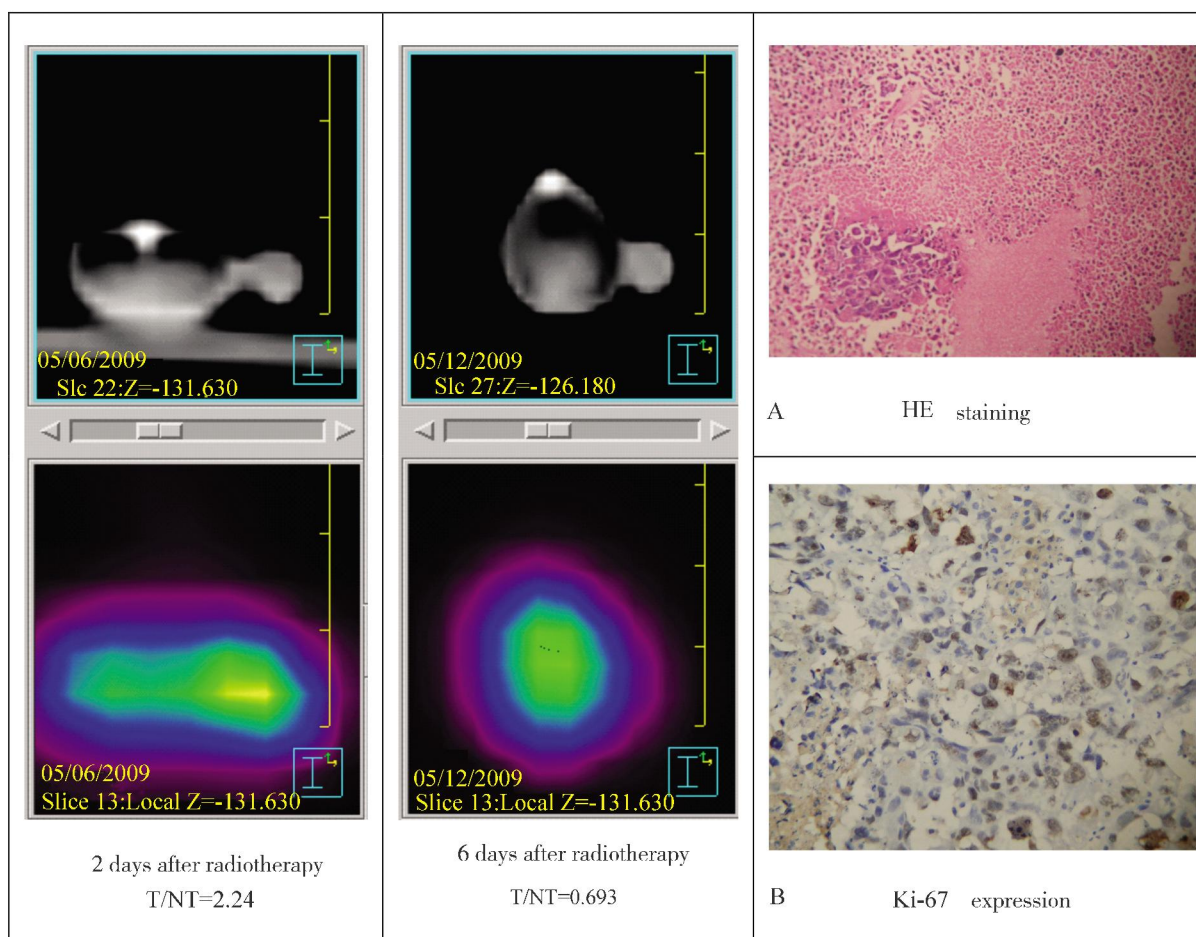


Figure 2 In Mouse 2, the results of ^{18}F -FDG PET-CT imaging, pathology, and immunohistochemistry

The tumor target/non-target (T/NT) ratios of ^{18}F -FDG PET-CT imaging on day 2 and day 6 post-radiotherapy were 2.24 and 0.693, respectively.

A, histopathology specimen ($\times 20$) shows the tumor cells near death after 6 days of post-radiotherapy, and occasionally shows a small nest of tumor cells; B, high-power ($\times 400$) view of histopathology specimen shows the proliferation marker (Ki-67) expression almost appears negative.

Gy/d) and PET-CT imaging at different times according to the literature^[10,11]. Semiquantitative results (T/NT ratios) showed that in these 5 mice the T/NT ratios of xenografts before radiotherapy and on days 2, 4, and 6 after radiotherapy had a clear downward trend with a significant difference between day 6 after radiotherapy and the rest of the time ($P < 0.005$), and the T/NT ratio on day 6 after radiotherapy was significantly lower than the opposite background tissue. Thus, the T/NT ratio measured in ^{18}F -FDG PET-CT imaging has an important value in evaluating the early efficacy of radiotherapy in nude mice with NPC xenografts, and the 6th day after radiotherapy may be an appropriate time point for imaging. However, due to the limitations of the experimental sample in this study and the difference between animal experiments and the clinic, whether the choice of this time point is suitable for evaluating the early efficacy of radiotherapy in clinical patients with NPC remains to be confirmed by further studies. At the same time, measured by the ROI technique on CT images, the tumor volumes of NPC xenografts before radiotherapy and on days 2, 4, and 6 after radiotherapy had no significant change, which also indicates that traditional imaging methods, such as CT, have low sensitivity

and specificity in evaluating the early efficacy of radiotherapy for NPC^[6].

It is generally believed that the scanning time for ^{18}F -FDG PET-CT delayed imaging is mostly 2–3 h after the injection of ^{18}F -FDG^[12]. This is because benign tumors, inflammatory disease, and malignant tumors have different transforming rates from hexokinase (HK) to glucose-6-phosphatase (G6P), leading to different ^{18}F -FDG uptake rates in these tissues^[13]. The uptake peak time of ^{18}F -FDG in inflammatory tissue is about 50–60 min after the injection, while it is about 3–4 h after injection in malignant tumors. Therefore, it has been reported that ^{18}F -FDG PET delayed imaging is more useful for differentiating malignant tumors from benign tumors and inflammatory disease^[13,14]. However, in the 7 animals with NPC xenografts in this study, the T/NT ratios in early and 3-h delayed imaging had no statistical significance ($P > 0.05$), indicating that ^{18}F -FDG PET-CT delayed imaging might not be meaningful for the diagnosis of NPC, which is consistent with the results reported by Yen *et al.* and Ng *et al.*^[8,15]. The reason may be that the uptake peak time of ^{18}F -FDG in NPC is less than 3 h, while the tumor FDG uptake has passed its peak and begins to decline at the 3-h delayed imaging^[16].

In summary, ^{18}F -FDG PET-CT has an important value in evaluating the early efficacy of radiotherapy in nude mice with NPC xenografts, and the 6th day after radiotherapy may be an appropriate time point. The T/NT ratio determined in ^{18}F -FDG PET-CT delayed imaging before radiotherapy might not be meaningful for the diagnosis of NPC.

References

- [1] Yan HY, Wang DY. Evaluation of enhanced CT examination in the differential diagnosis of local recurrence and postradiation fibrosis in nasopharyngeal carcinoma [J]. Chin J Oncol, 1997,19 (3):203–205. [in Chinese]
- [2] Zhou W, Yin DZ, Wang YX. Small animal PET [J]. Nucl Tech, 2006,29(3): 207–213. [in Chinese]
- [3] Strauss LG, Conti PS. The application of PET in clinical oncology [J]. J Nucl Med, 1991,32(4):623–648.
- [4] Haberkorn U, Strauss LG, Antonia D, et al. Fluorodeoxyglucose imaging of advanced head and neck cancer after chemotherapy [J]. J Nucl Med, 1993,34(1):12–17.
- [5] Chen YR, Gu MX, Li WX, et al. Detection of residue of nasopharyngeal carcinoma with FDG PET [J]. Chin J Cancer, 2002,21 (6):651–653. [in Chinese]
- [6] Zhang WJ, Zheng R, Wu N. Application of ^{18}F -fluorodeoxyglucose PET in nasopharyngeal carcinoma [J]. Int J Radiat Med Nucl Med, 2006,30(2): 94–97. [in Chinese]
- [7] Mitsuhashi N, Hayakawa K, Hasegawa M, et al. Clinical FDG PET-CT in diagnosis and evaluation of radiation response of patients with nasopharyngeal tumor [J]. Anticancer Res, 1998,18(4B):2827–2832.
- [8] Yen TC, Chang JT, Ng SH, et al. The value of ^{18}F -FDG PET in the detection of stage M0 carcinoma of the nasopharynx [J]. J Nucl Med, 2005,46(3):405–410.
- [9] Peng N, Yen S, Liu W, et al. Evaluation of the effect of radiation therapy to nasopharyngeal carcinoma by positron emission tomography with 2-F- ^{18}F fluoro-2-deoxy-D-glucose [J]. Clin Positron Imaging, 2000,3(2):51–56.
- [10] Molthoff CFM, Klabbers BM, Berkhof J, et al. Monitoring response to radiotherapy in human squamous cell cancer bearing nude mice: comparison of 2-deoxy-2-[^{18}F]fluoro-D-glucose(FDG) and 3-[^{18}F]fluoro-3-deoxythymidine(FLT) [J]. Mol Imaging Biol, 2007(9):340–347.
- [11] Xia YF, Huang B, Dong XY, et al. Experimental Study of Radiation Biology with Human nasopharyngeal carcinoma cell line (CNE-2) [J]. Chin J Cancer, 1999,(1):86–87. [in Chinese]
- [12] He XH, Feng YL, Yu FW, et al. Technical aspect on calculating the acquisition parameters for delayed ^{18}F -FDG PET/CT imaging [J]. Chin J Nucl Med, 2007,27(1):41–42. [in Chinese]
- [13] Zhuang H, Pourdehnad M, Lambright ES, et al. Dual time point ^{18}F -FDG PET imaging for differentiating malignant from inflammatory processes [J]. J Nucl Med, 2001,42(9):1412–1417.
- [14] Kubota K, Itoh M, Ozako K, et al. Advantage of delayed whole-body FDG-PET imaging for tumor detection [J]. Eur J Nucl Med, 2001,28(6): 696–703.
- [15] Ng SH, Joseph CT, Chan SC, et al. Clinical usefulness of ^{18}F -FDG PET in nasopharyngeal carcinoma patients with questionable MR findings for recurrence [J]. J Nucl Med, 2004,45(10):1669–1676.
- [16] Yen TC, Chang YC, Chan SC, et al. Are dual-phase ^{18}F -FDG PET scans necessary in nasopharyngeal carcinoma to assess the primary tumor and loco-regional nodes? [J]. Eur J Nucl Med Mol Imaging, 2005,32(5):541–548.